Imaging of the Stomach

- Barium Meal
  - Stomach distended with gas producing agent + IV injection of short acting smooth muscle relaxant
  - Barium – 200mls
  - Images taken in various positions – allowing barium to coat mucosa
  - Role:
    - Failed gastroscopy, assessment of duodenal strictures, assessment of functional patency/gastric emptying, rule out/confirm anastomotic leak following surgery
- CT stomach + duodenum
  - Good patient preparation – ensure food residue does not mimic pathology
  - Oral + IV CM used
  - Role:
    - Stage extraluminal extent of any disease, especially carcinoma
    - Further evaluate stomach – suspicion of an external mass compressing stomach

Dx of the Stomach

- Hypertrophic pyloric stenosis
- Peptic ulcer
- Gastritis
- Hiatal Hernia
- Tumours
  - Benign
  - Adenocarcinoma

Congenital Dx

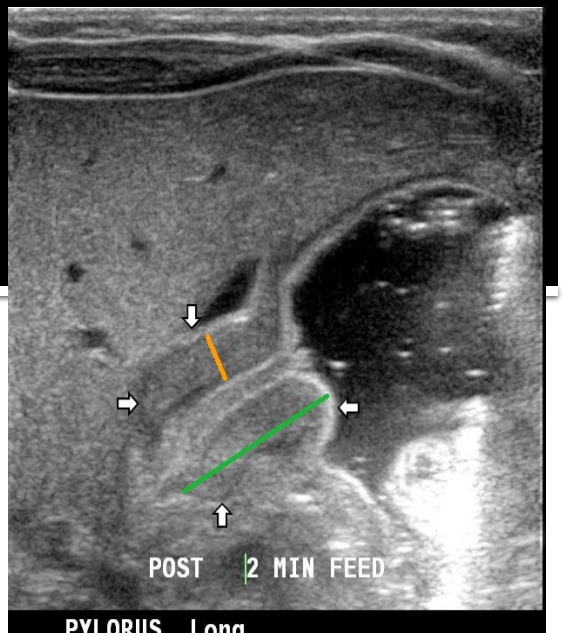

- **Hypertrophic pyloric stenosis** – greatly narrowed pyloric canal – due to hypertrophy of sphincter
  - Common indication for surgery in infants
  - Males > females X 3
  - Signs & symptoms
    - Projectile vomiting @ 3 – 5 weeks
    - dehydration & failure to thrive
  - Imaging:
    - Abd US – very useful in evaluating hypertrophy
    - Upper GI series – delayed gastric emptying with distention + classic "string sign" as barium trickles thru narrowed canal

(Mace & Kowalczyk, p113)

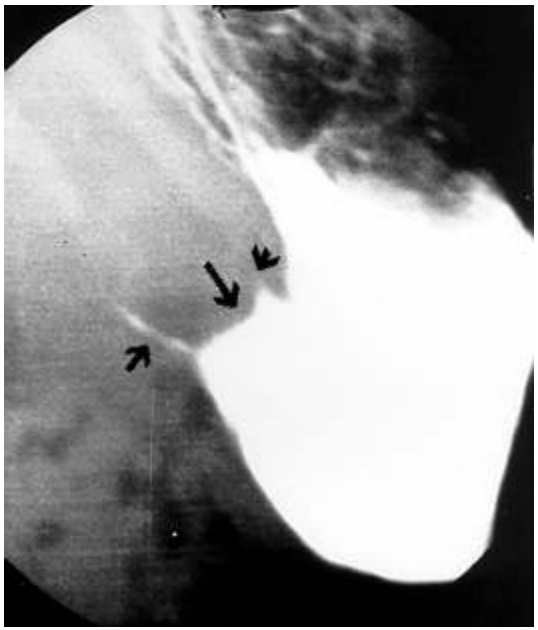

Inflammatory Dx

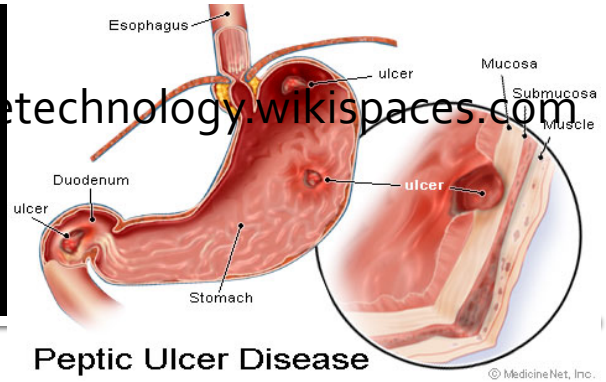

- **Peptic ulcer** – erosion of mucous membrane of lower end of oes, stomach & duodenum
  - Common sites duodenal bulb & lesser curvature of stomach
  - Duodenal ulcers affect adults of all ages, but > 40 years
  - Result form disruption of normal mucosal defense & repair mechanisms
    - NSAIDs
    - Helicobacter pylori
  - Main symptom – pain above epigastrium & radiating to all parts of abdomen when stomach empty – begins midmorning, subsides with food intake but returns 2 to 3 hrs later
    - Food provides temporary relief
    - In some patients food actually ↑ pain

http://www.hopkins-gi.org

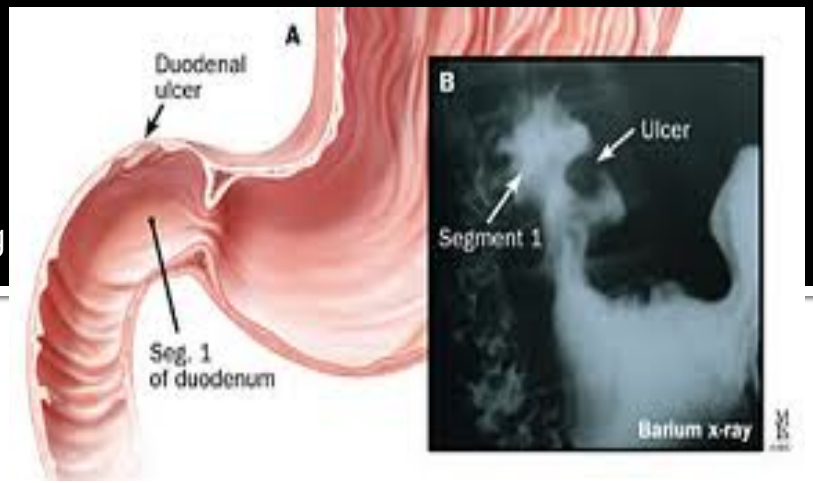

- Diagnosis – primarily by endoscopy
- Radiography: double-contrast upper GI series
  - Gastric ulcers – radiating spike-like wheels of mucosal folds that run to edge of crater
  - Seen end-face – appears round & regular
- Complications – bleeding & perforation → peritonitis or pneumoperitoneum

(refer Eisenberg & Johnson, p 181)


http://www.drdach.com

- **Gastritis** – inflammatory disorder of stomach & intestines
  - Erosive gastritis → precursor to gastric ulcer formation
  - Complete erosions may be seen as slit-like collections of barium surrounded by radiolucent halos of swollen elevated mucosa
    - Also, scalloped/nodular antral folds may be seen
  - Antral gastritis is demonstrated by increased distention of antrum in combo with thickened mucosal folds - oriented on its longitudinal axis → narrowed antrum
  - Food poisoning → mild mucosal ulcerations → diarrhoea
    - Patient management is important

http://www.fmhs.auckland.ac.nz

(refer Eisenberg & Johnson, p179)

DEGENERATIVE DISEASES

- **Herniation** – protrusion of loop of bowel thru small opening in abdominal wall (due to rupture/anatomic weakness)
  - As loop herniates it pushes peritoneum with it
  - Inguinal hernia – bowel loop protrudes thru inguinal ring and may descend into scrotum (common in men)
  - Femoral & umbilical herniation affects both sexes
  - Reducible ← If the herniation can be pushed back
  - Incarcerated ← If becomes stuck & cannot be reduced
  - Can result in bowel obstruction
  - Strangulated ← If constriction thru which bowel passed is tight enough to cut off blood supply → prompt surgical intervention to avoid bowel necrosis

http://www.radiology2020.blogspot.com

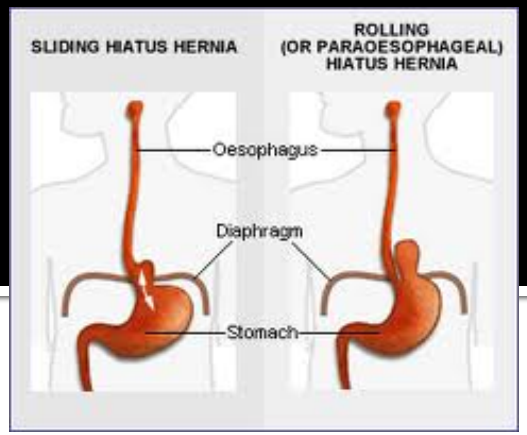

- **Hiatal hernia (HH)** – weakness of oesophageal hiatus – allows some portions of the stomach to herniate into thoracic cavity

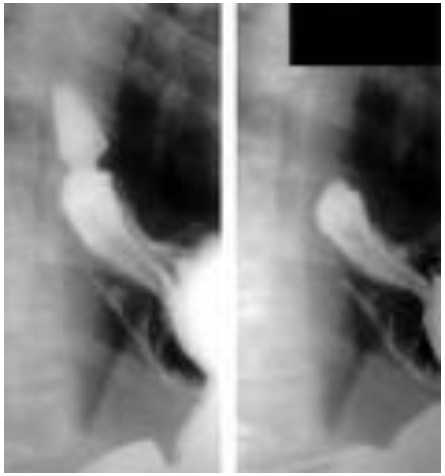

  - HH occurs in about ½ population over 50 years
  - Early stages – reducible
  - Chronic HH – associated with GERD
  - A **direct or sliding HH** (99%)– when portion of the stomach & gastroesophageal junction are pushed above diaphragm
    - Schatzki's ring is visible & consists of mucosal ring that protrudes into lumen → no clinical significance unless causes dysphagia due to narrowing

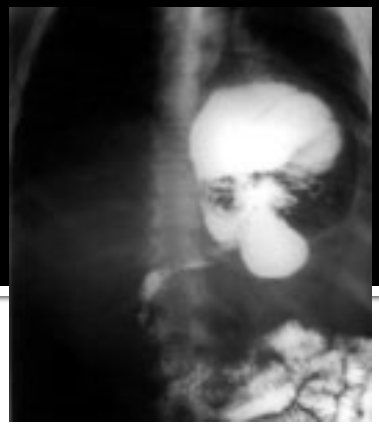

- **Rolling or paraoesophageal** (less common) – when a portion of stomach & adjacent viscera herniate above diaphragm while GOJ remains below
  - If all of stomach slides thru → intrathoracic stomach
  - Potentially life threatening ← risk of volvulus, incarceration or strangulation
- Most HH are asymptomatic,
- Some have reflux, complain of full feeling post meals, heartburn
- Barium meals – pinpoint presence & type of HH

(refer Eisenberg & Johnson, p174)

Tumours of Stomach

- Benign tumours < 10%
- Those clinically significant – rare
- Most tumours – malignant → **adenocarcinomas**
  - Incidence varies according to geographic area, race, diet, heredity & gender.
  - Poor prognosis – overall 5 yr survival rates < 20%
  - Develop in pylorus & antrum along lesser curvature (present anywhere)
  - May be polypoidal with plaque-like lobulated appearance
  - Diagnosed mostly @ advanced stage of dx – mostly due to non-specific symptoms in early stage
  - Invade other structures by variety of routes
  - Metastasise – omentum, pancreas, colon & liver

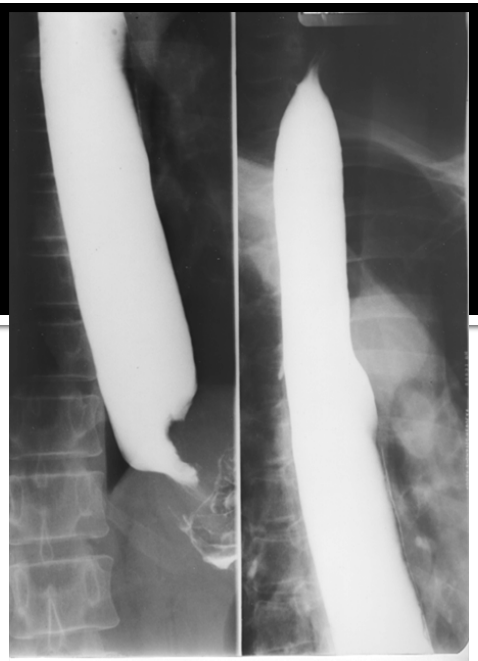

- Liver involvement → discharges into bloodstream & disperses thru'out body
- Abundance of lymphatics in stomach – metastasise via lymphatics
- Clinically:
  - Persistent pain, bleeding, loss of appetite, weight loss, & early satiety
- Imaging: endoscopy with biopsy, upper GI series (CM), CT – staging
- Radiographically:
  - relative rigidity of peristalsis & filling defects on compression (areas of total/relative radiolucency within barium column. Polypoids tumours are seen on CT
- Treatment: surgery, radiation therapy, chemotherapy.

(refer Eisenberg & Johnson, p185)

REFERENCES

- Reid and Robert, **Pathology Illustrated**, Elsevier Churchill Livingstone
- Eisenberg and Johnson, **Comprehensive Radiographic Pathology**, Elsevier Mosby
- Mace and Kowalczyk, **Radiographic Pathology for Technologists,** Mosby
- Armstrong, Rockall and Wastie, **Diagnostic Imaging**, Blackwell Scientific
- Grainger and Allison, **Diagnostic Radiology**, Churchill Livingstone
- Martin, E.A (editor), **Oxford Concise Medical Dictionary**
- Medcyclopaedia, **Textbook of Radiology** – http://www.medcyclopaedia.com/library/radiology.aspx
- eMedicine – http://emedicine.medscape.com
- Images – Courtesy of Dr Jackpersad + Radiography Museum, DUT + via Google Images